

Restoration-Guided Implant Rehabilitation of the Complex Partial Edentulism: a Clinical Report

Fotios Tzerbos¹, Nikitas Sykaras², Vasilios Tzoras³

¹Assistant Professor, Department of Oral & Maxillofacial Surgery, Dental School, University of Athens, Greece

²Lecturer, Department of Prosthodontics, Dental School, University of Athens, Greece

³Private Practice, Agrinio, Greece

Corresponding Author:

Nikitas Sykaras

Nikis 25

GR-15233, Halandri

Greece

Phone: +30 210 6800 636

Fax: +30 210 7236051

E-mail: nsykaras@otenet.gr

ABSTRACT

Background: The hard and soft tissue deficiency is a limiting factor for the prosthetic restoration and any surgical attempt to correct the anatomic foundation needs to be precisely executed for optimal results. The purpose of this paper is to describe the clinical steps that are needed to confirm the treatment plan and allow its proper execution.

Methods: Team work and basic principles are emphasized in a step-by-step description of clinical methods and techniques. This clinical report describes the interdisciplinary approach in the rehabilitation of a partially edentulous patient. The importance of the transitional restoration which sets the guidelines for the proper execution of the treatment plan is especially emphasized along with all the steps that have to be followed.

Results: The clinical report describes the diagnostic arrangement of teeth, the ridge augmentation based on the diagnostic evaluation of the removable prosthesis, the implant placement with a surgical guide in the form of the removable partial denture duplicate and finally the special 2-piece design of the final fixed prosthesis.

Conclusions: Clinical approach and prosthesis design described above offers a predictable way to restore partial edentulism with a fixed yet retrievable prosthesis, restoring soft tissue and teeth and avoiding an implant supported overdenture.

Keywords: dental implants; implant-supported dental prosthesis; surgical diagnostic technique; planning techniques; diagnostic techniques and procedures.

Accepted for publication: 24 November 2009

To cite this article:

Tzerbos F, Sykaras N, Tzoras V. Restoration-guided implant rehabilitation of the complex partial edentulism: a clinical report
J Oral Maxillofac Res 2010 (Jan-Mar);1(1):e8

URL: <http://www.ejomr.org/JOMR/archives/2010/1/e8/e8ht.pdf>

doi:[10.5037/jomr.2010.1108](https://doi.org/10.5037/jomr.2010.1108)

INTRODUCTION

Dental implants are used widely in clinical dentistry today to restore partial or complete edentulism [1]. The longevity of the implants and the supported restoration depend on a great degree of the careful evaluation of clinical parameters, the proper design of the treatment plan and its precise execution [2,3]. Modern techniques and new protocols offer predictable solutions in almost any therapeutic intervention by solving functional problems and achieving at the same time an aesthetic result. The interdisciplinary approach of the described clinical report emphasizes the need for “restoration guided” implant rehabilitation through the preoperative establishment of the final therapeutic goal on the diagnostic casts [4,5]. The planned restoration must be tested and either accepted or modified in the clinical environment in order to guide the correct position of the dental implants which in turn allow their proper restoration.

In the described clinical case the following problems could be identified: the disturbance of the occlusal plane, the lack of anterior guidance, the reduced vertical dimension, the reverse smile line, the missing teeth and the unaesthetic appearance. Both the presence of severe anatomical deficits and a faulty prosthesis were acting in synergy to create a major problem for the patient who was complaining for limited function, aesthetics and phonetics.

American College of Prosthodontists (ACP) has developed a classification system (I-IV) for the partial edentulism based on diagnostic criteria and according to that the patient described herein presents a Class IV edentulism which is characterized by severely compromised location and extent of edentulous areas [6]. The diagnosis of the aforementioned clinical findings necessitates the reestablishment of the missing guidelines through the diagnostic arrangement of artificial teeth and the clinical testing of provisional restorations that set the framework for the next clinical

level. The hard and soft tissue deficiency is a limiting factor for the prosthetic restoration and any surgical attempt to correct the anatomic foundation needs to be precisely executed for optimal results.

The purpose of this paper is to describe the clinical steps that are needed to confirm the treatment plan and allow its proper execution. Team work and basic principles are emphasized in a step-by-step description of clinical methods and techniques.

CASE DESCRIPTION AND RESULTS

The patient was a 40 year old Caucasian male who had lost his maxillary teeth from the right canine (tooth #13) to left first molar (tooth #26) at the age of 19 due to an accident. He wore a removable partial denture in the maxilla since that age and sought treatment to improve function and aesthetics. The existing fixed partial denture in the mandible was extending from the right first premolar (tooth #44) to the right third molar (tooth #48) and the mandibular left first and second molars were missing (Figure 1). The patient’s past medical history was negative, he has never been hospitalized, not currently under any medication and smoking habits were absent.

A record base with a wax rim was initially used to record the centric relation and along with a face-bow

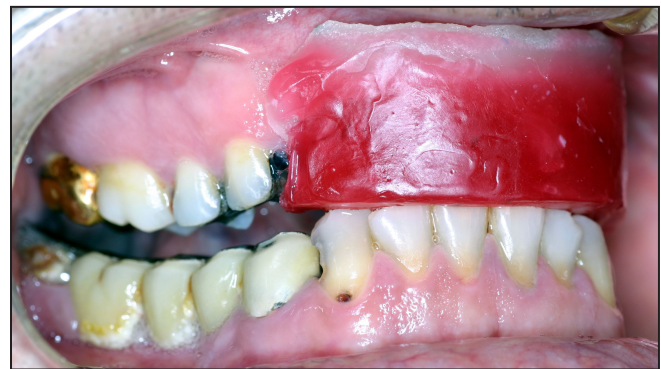

Figure 2. Centric relation recording at the determined vertical dimension.

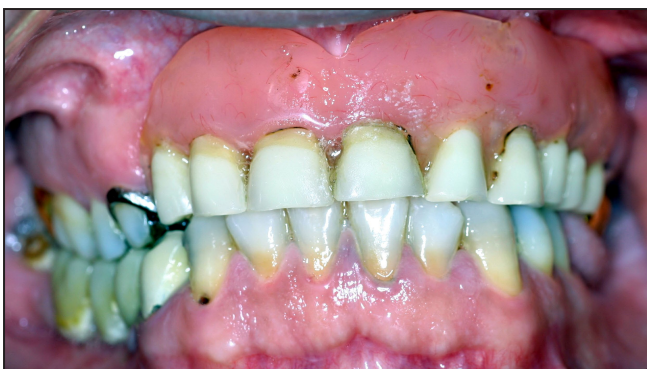

Figure 1. Intraoral pretreatment situation.

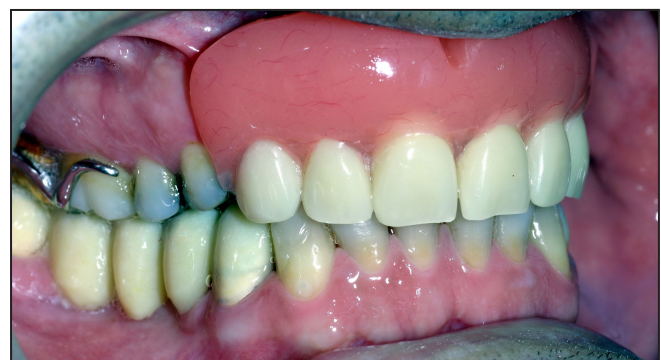

Figure 3. Provisional maxillary removable partial denture.

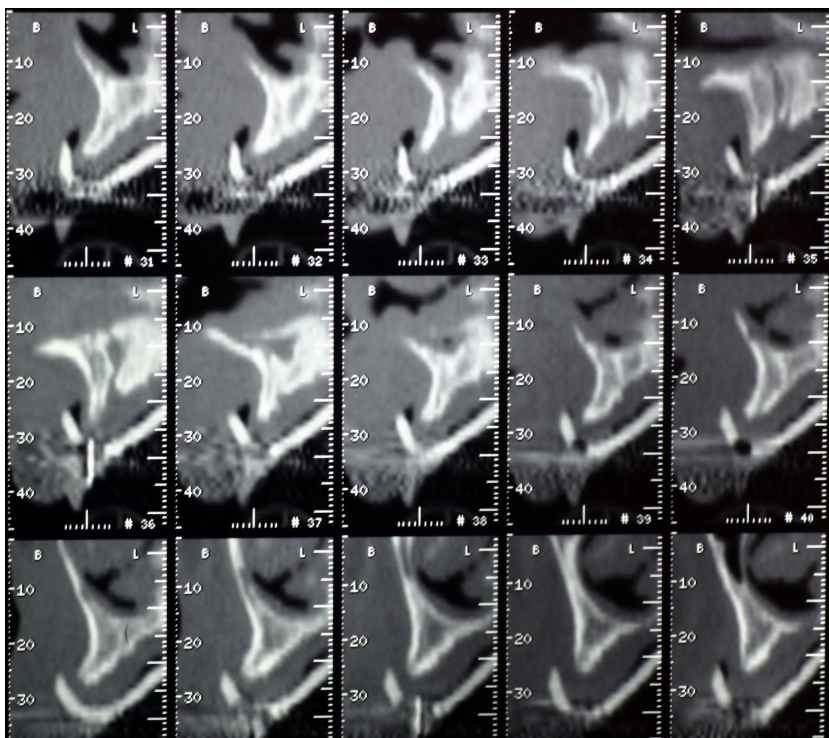


Figure 4. Presurgical computed tomography of the maxilla.

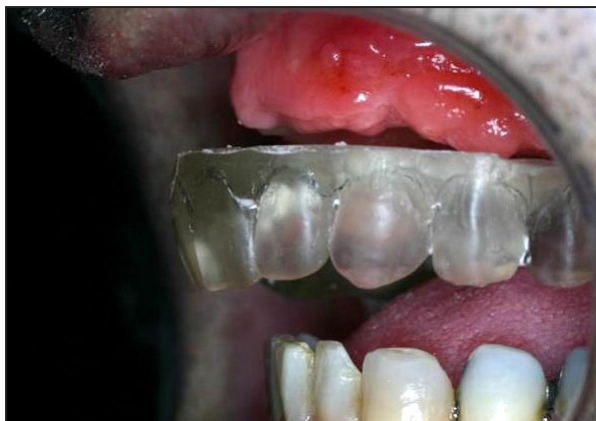

Figure 5. Duplicate of the confirmed teeth arrangement in relation to the anterior maxillary ridge presurgically.

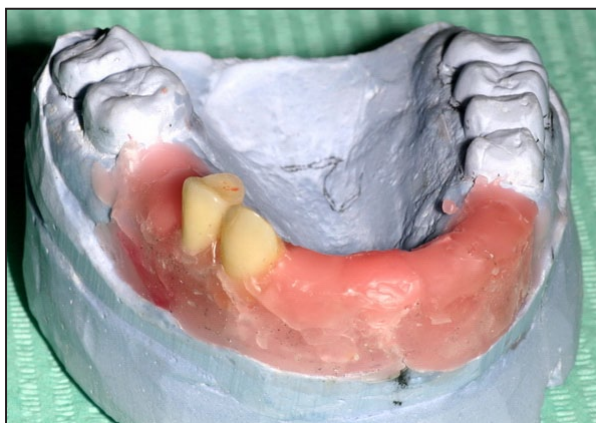


Figure 6. Removable partial denture teeth arrangement is transferred with a silicone key on a duplicate of the maxillary working cast and stabilized with wax only.

transfer of the maxillary cast they were used to ensure the accurate mounting on the articulator (Figure 2). The conventional methods and techniques employed in the removable prosthodontics were used to shape the wax rim and determine the occlusal plane and the vertical dimension of occlusion (VDO). The clinical trial of the maxillary missing teeth at the determined VDO revealed their dramatic effect on the improvement of the facial aesthetics but the patient had to go through a transitional period to assess the proposed treatment plan. For this reason a maxillary splint in the form of a provisional removable partial denture (RPD) was delivered to the patient for a period of two months and was accompanied with a metal reinforced provisional acrylic fixed partial denture extending from mandibular right first premolar to third molar (Figure 3). No clinical signs and symptoms for the patient were recorded at the end of the trial period and the validity of the therapeutic goal was initially confirmed. The treatment options involved the fabrication of a maxillary RPD or an implant supported fixed prosthesis.

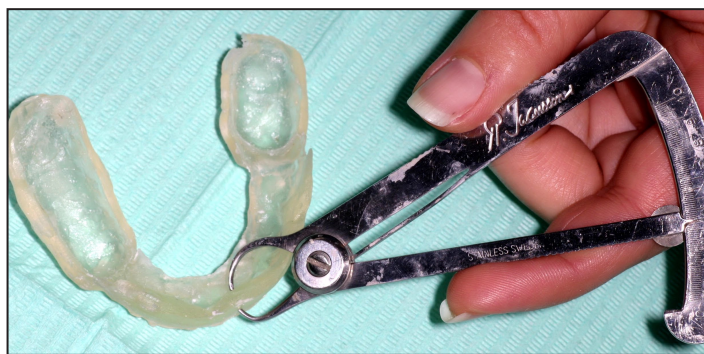


Figure 7. Processing of the "wax ridge" in clear acrylic.

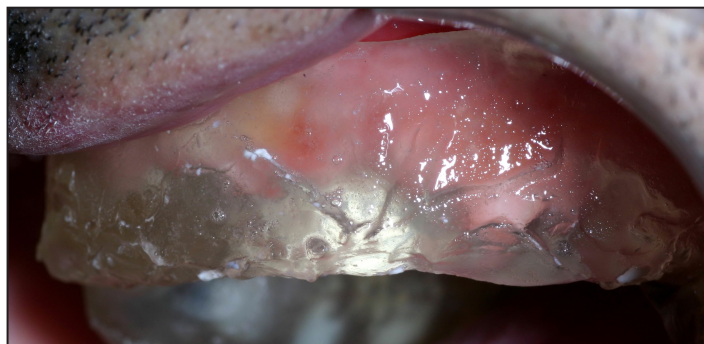


Figure 8. Evaluation of clear acrylic allowed better estimation of the bone graft quantity and shape.

The patient expressed the wish for a fixed metal ceramic restoration and the treatment plan of implant insertion was initiated. The patient have read and signed informed consent form.

The patient should go through a surgical phase to augment the maxillary ridge and render it suitable for implant insertion. Computed tomography assessment revealed bone deficiency in height and width (Figure 4). In order to better evaluate the amount of bone and the shape that it had to be given, a presurgical evaluation was performed in the following way: the arrangement of the denture teeth was duplicated and stabilized on the cast with wax without any base plate. Removal of the denture teeth and processing of the remaining stabilizing wax “ridge” in clear acrylic provided a solid duplicate of the bony graft (Figures 5-8). This solid duplicate allowed for the exact dimensions of the bone

graft which was harvested from the area of mandibular symphysis. Reconstruction of the edentulous maxilla was planned on a horizontal and vertical plane. A cortical bone graft was removed from the donor site between the mental foramina and divided in two uneven pieces. All the cancellous bone up to the lingual cortical plate was removed using osteotomes and surgical curettes. The donor site was refilled with a xenograft (Bio-Oss, Geistlich, Wolhusen, Switzerland) and was covered with a collagen type resorbable membrane (Bio-Gide, Geistlich, Wolhusen, Switzerland). The flaps over the donor site were sutured in a two layer fashion using resorbable sutures. The recipient deficient areas of the maxilla were properly prepared and the two cortical bone grafts were stabilized using bone screws. The larger cortical block was placed on the left side and the smaller one on the right side. All

the empty spaces around the grafts were filled with a mixture of autogenous bone graft and a xenograft (Bio-Oss Geistlich, Wolhusen, Switzerland), in an effort to shape the reconstructed maxilla according to the solid duplicate of the “wax” ridge. Non-resorbable membranes (Gore-Tex, Gore, Elkton MD, USA) covered the grafted sites and were stabilized with pins, 1.2 mm in diameter. At the same time a maxillary sinus augmentation operation using lateral window approach was performed and the area was filled using a mixture of autogenous bone graft and xenogenic grafting material (Bio-Oss, Geistlich, Wolhusen, Switzerland). Special attention was given to the tension free closure of the flaps. Therefore after the proper wound margins adaptation the surgical area was sutured using 4-0 Vicryl resorbable sutures (Ethicon, W. Somerville, NJ, USA). The procedure was performed

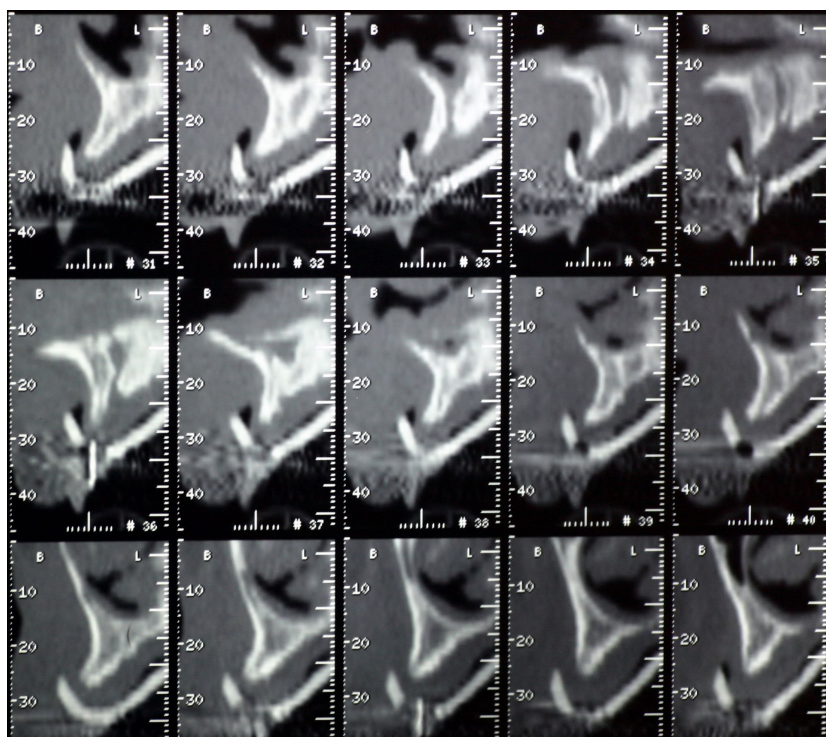


Figure 9. Postsurgical computed tomography of the maxilla.

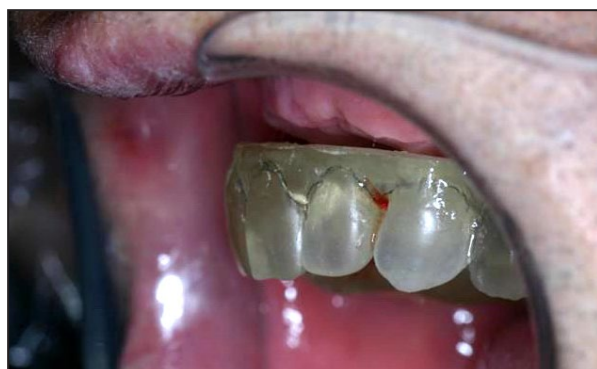

Figure 10. Duplicate of the confirmed teeth arrangement in relation to the anterior maxillary ridge postsurgically.

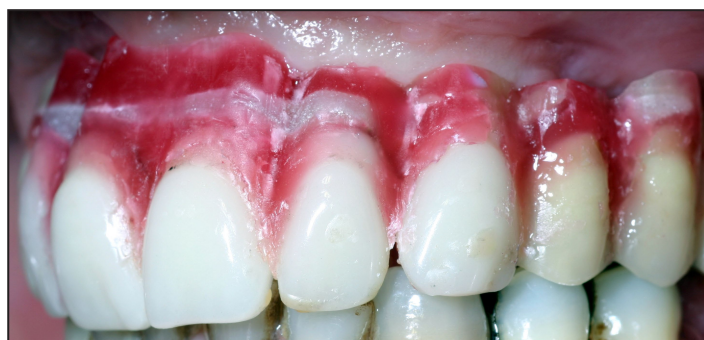

Figure 11. Removable partial denture teeth arrangement is transferred to the augmented maxilla with a record base for the evaluation of teeth position and soft tissue deficiency.

under local anaesthesia with intravenous sedation and the postoperative period was uneventful. The RPD was relined with a tissue conditioning material Visco-gel (Dentsply, Konstanz, Germany) every 2 weeks for the entire healing period, to reduce pressure effects on the grafted site.

After 5 months, the non-resorbable membrane on the right side was exposed. Since there were no signs of infection and this happened almost at the end of the sixth month healing period, it was decided not to remove the membrane at that time, but to wait for an additional month while evaluating the grafting procedure with a new computed tomography and the clear duplicate of diagnostic teeth arrangement (Figures 9-10). At that

time, there were no signs of numbness of the lower anterior teeth or the lip. The patient was instructed in proper oral hygiene and when the healing period of 6 months was completed, a new impression of the augmented maxilla was made and the previously used diagnostic arrangement of denture teeth was adapted to the new tissue surface with wax and stabilized with a palatal base plate. Clinical trial in the patient's mouth (Figure 11) confirmed the correct position of the teeth and its duplication in heat cured clear acrylic provided a radiographic template (Figure 12). Radiopaque markers were inserted in the palatal or occlusal surfaces of

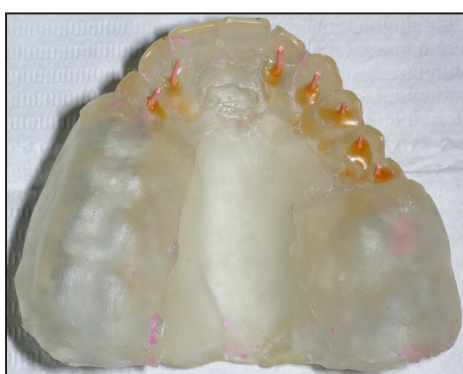

Figure 12. Radiographic template.

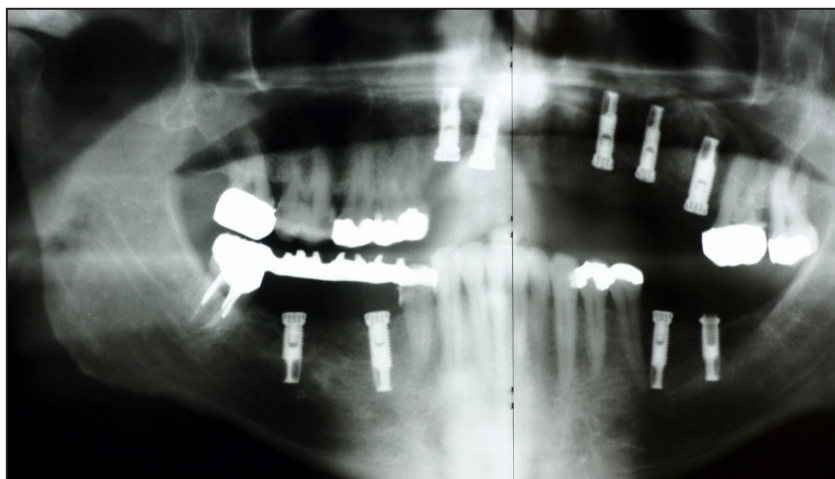


Figure 13. Implants inserted in the maxilla and mandible.

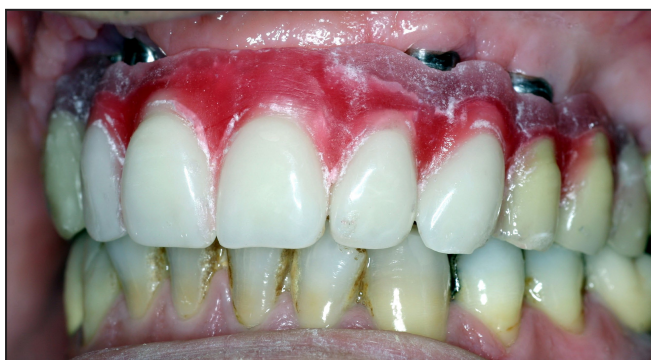

Figure 14. Clinical trial placement stabilized on maxillary implants.

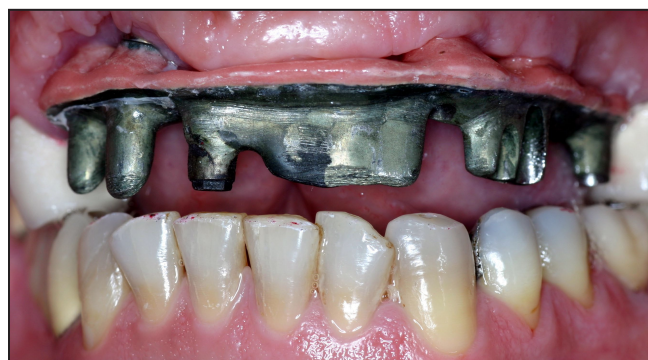

Figure 15. Screw-retained infrastructure veneered with pink composite.

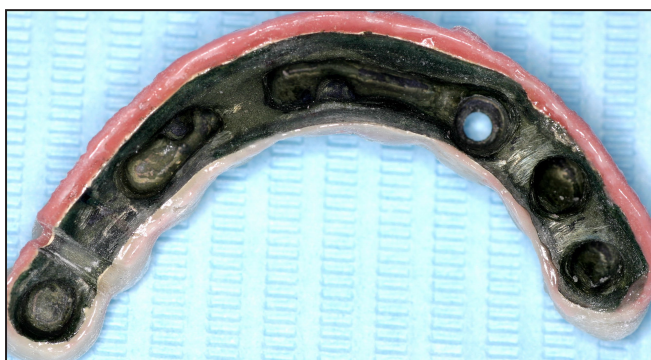

Figure 16. Intaglio surface of cement retained superstructure. The hole for the set screw is visible.

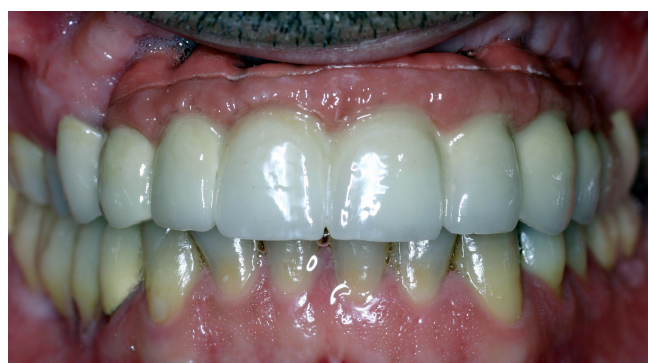

Figure 17. Intraoral view of final prosthesis.

all missing teeth and a computed tomography was performed. The analysis of the tomograms, the evaluation of the grafted ridge and the consideration of the final prosthesis design, set the guidelines for implant position modifications and led to the fabrication of the surgical guide for implant placement.

Upon completion of the preoperative work up the patient underwent the second surgical procedure. The screws, the pins and the non-resorbable membranes were removed from the grafted sites and five Brånemark System implants (Nobel Biocare AB, Göteborg, Sweden) were inserted in the maxillary edentulous segment and four implants bilaterally in the mandible (Figure 13). All implants were submerged and the surgery was performed under local anaesthesia with intravenous sedation. The postoperative period was uneventful. The second stage surgery was performed five months later and all implants were osseointegrated.

Implant impression was followed by fabrication and mounting of the working casts which allowed the final evaluation of implant inclination, interocclusal space and amount of soft tissue deficiency that had to be built into the final prosthesis. Two modified temporary cylinders were attached to the implants and allowed the clinical try-in of the initial teeth set-up (Figure 14). The correct teeth position was confirmed again and a silicon key was then fabricated to guarantee the exact reproduction in porcelain. Metal framework was tried in for passivity, followed by bisque bake check and the final glazed prosthesis was made in two segments: 1) a primary base with built-in metal abutments veneered with pink composite (GC Gradia Gum, GC, Tokyo, Japan) and 2) a secondary PFM prosthesis apically covered with pink porcelain that was cemented to the primary base with temporary cement and secured with a small occlusal screw (Figures 15-17). Restoration of the mandible with fixed prostheses, in conjunction with maxillary restoration allowed for correction of occlusal plane and improvement of function and aesthetics.

DISCUSSION

This clinical report emphasizes the importance of pre-surgical planning for the complex implant rehabilitation, presenting the correct application of clinical methods usually employed in the treatment of complete edentulism. Analysis of teeth and base of the transitional removable prosthesis gave the opportunity to evaluate separately the position of the teeth and the hard and soft tissue deficiency. The surgical guide presented herein allowed the exact harvesting and the correct shaping of the grafting material generating the bone substrate for the implant placement at a later time.

Autologous bone grafts are the gold standard for the restoration of atrophic mandible and maxilla and implant placement is more predictable when it takes place secondarily after 6 - 9 months [7]. There are various extraoral or intraoral donor sites for the bone graft. In this clinical case, the amount of necessary bone graft dictated by the ridge wax duplicate could be adequately replaced using an intraoral block graft instead of necessitating extraoral graft harvesting. Besides the area of the mandibular symphysis another possible intraoral donor site is the ramus and the external oblique line of the mandible. We decided not to operate and intervene in an area that implants were planned to be inserted later. Although resorption of onlay grafts occurs at various rates depending on the donor site and the technique employed, the success rate of the implants inserted secondarily is not affected; and *vice versa* implant failure does not imply failure of the bone graft [8].

According to the literature, if there is an exposure of a non-resorbable membrane, various amounts of bone loss are expected in the reconstructed area. In this clinical report, exposure of the membrane happened at the end of the healing period and was not an influencing factor [9,10]. Rather, the atrophy of the maxilla was so extreme initially and difficult to be compensated precisely and predictably, that ended in a small hard and soft tissue deficiency at the initiation of the prosthetic restoration phase. Such clinical situations can be restored with a removable or fixed prosthesis. However, in augmented bone, fixed restorations present higher success rates compared to removable prostheses [11,12].

The advantages of a two segment fixed prosthesis have been described in the past with various designs and retention configurations [13-15]. Dividing the prosthesis into two pieces allows for better control of metal distortion during porcelain application and almost eliminates the occlusal disturbance of the screws' exit. The palatal set screw incorporated into the prosthesis further enhances the confidence of cement retention yet allowing retrievability. With the two piece framework design the primary base acts as a splint for the maxillary implants dissipating the functional loading in a more favourable and protective pattern into the grafted bone [16]. The veneering of the primary base with pink resin allows easier modification and repair of the emergence profile of the prosthesis in the event of tissue resorption. Restoration of the mandibular edentulous spaces that was performed at the same time, allowed the occlusal plane correction, posterior support and improved function and aesthetics.

CONCLUSIONS

Clinical approach and prosthesis design described above offers a predictable way to restore partial edentulism with a fixed yet retrievable prosthesis, restoring soft tissue and teeth and avoiding an implant supported overdenture.

ACKNOWLEDGMENTS AND DISCLOSURE STATEMENTS

The authors report no conflicts of interest related to this study.

REFERENCES

1. Wood MR, Vermilyea SG; Committee on Research in Fixed Prosthodontics of the Academy of Fixed Prosthodontics. A review of selected dental literature on evidence-based treatment planning for dental implants: report of the Committee on Research in Fixed Prosthodontics of the Academy of Fixed Prosthodontics. *J Prosthet Dent.* 2004 Nov;92(5):447-62. [Medline: [15523334](#)] [doi: [10.1016/j.prosdent.2004.08.003](#)]
2. Pjetursson BE, Lang NP. Prosthetic treatment planning on the basis of scientific evidence. *J Oral Rehabil.* 2008 Jan;35 Suppl 1:72-9. [Medline: [18181936](#)] [doi: [10.1111/j.1365-2842.2007.01824.x](#)]
3. Higginbottom F, Belser U, Jones JD, Keith SE. Prosthetic management of implants in the esthetic zone. *Int J Oral Maxillofac Implants.* 2004;19 Suppl:62-72. [Medline: [15635946](#)]
4. Salinas TJ, Sheridan PJ, Castellon P, Block MS. Treatment planning for multiunit restorations--the use of diagnostic planning to predict implant and esthetic results in patients with congenitally missing teeth. *J Oral Maxillofac Surg.* 2005 Sep;63(9 Suppl 2):45-58. [Medline: [16125015](#)] [doi: [10.1016/j.joms.2005.05.155](#)]
5. Garber DA. The esthetic dental implant: letting restoration be the guide. *J Am Dent Assoc.* 1995 Mar;126(3):319-25. [Medline: [7897100](#)] [[FREE Full text](#)]
6. McGarry TJ, Nimmo A, Skiba JF, Ahlstrom RH, Smith CR, Koumjian JH, Arbree NS. Classification system for partial edentulism. *J Prosthodont.* 2002 Sep;11(3):181-93. [Medline: [12237799](#)]
7. Keller EE, Tolman DE, Eckert S. Surgical-prosthodontic reconstruction of advanced maxillary bone compromise with autogenous onlay block bone grafts and osseointegrated endosseous implants: a 12-year study of 32 consecutive patients. *Int J Oral Maxillofac Implants.* 1999 Mar-Apr;14(2):197-209. [Medline: [10212536](#)]
8. Triplett RG, Schow SR. Autologous bone grafts and endosseous implants: complementary techniques. *J Oral Maxillofac Surg.* 1996 Apr;54(4):486-94. [Medline: [8600266](#)] [doi: [10.1016/S0278-2391\(96\)90126-3](#)]
9. Merli M, Bernardelli F, Esposito M. Horizontal and vertical ridge augmentation: a novel approach using osteosynthesis microplates, bone grafts, and resorbable barriers. *Int J Periodontics Restorative Dent.* 2006 Dec;26(6):581-7. [Medline: [17243331](#)]
10. Llambés F, Silvestre FJ, Caffesse R. Vertical guided bone regeneration with bioabsorbable barriers. *J Periodontol.* 2007 Oct;78(10):2036-42. [Medline: [18062126](#)]
11. Aghaloo TL, Moy PK. Which hard tissue augmentation techniques are the most successful in furnishing bony support for implant placement? *Int J Oral Maxillofac Implants.* 2007;22 Suppl:49-70. Erratum in: *Int J Oral Maxillofac Implants.* 2008 Jan-Feb;23(1):56. [Medline: [18437791](#)]
12. Laverick S, Summerwill A, Cawood JI. Ten years of experience with the anterior maxillary and mandibular osteoplasty (class IV ridges): a retrospective analysis of implant survival rates. *Int J Oral Maxillofac Surg.* 2008 May;37(5):415-8. Epub 2008 Mar 4. [Medline: [18308512](#)] [doi: [10.1016/j.ijom.2007.12.007](#)]
13. Hagiwara Y, Nakajima K, Tsuge T, McGlumphy EA. The use of customized implant frameworks with gingiva-colored composite resin to restore deficient gingival architecture. *J Prosthet Dent.* 2007 Feb;97(2):112-7. [Medline: [17341380](#)] [doi: [10.1016/j.prosdent.2006.12.011](#)]
14. McCracken M, Simmons B, Simmons W. Cement-retained superstructure for a metal-resin fixed complete denture. *J Prosthet Dent.* 2005 Mar;93(3):298-300. [Medline: [15775933](#)] [doi: [10.1016/j.prosdent.2004.12.014](#)]
15. Cobb GW Jr, Metcalf AM, Parsell D, Reeves GW. An alternate treatment method for a fixed-detachable hybrid prosthesis: a clinical report. *J Prosthet Dent.* 2003 Mar;89(3):239-43. [Medline: [126447K97](#)] [doi: [10.1067/mpr.2003.39](#)]
16. Naert I, Koutsikakis G, Duyck J, Quirynen M, Jacobs R, van Steenberghe D. Biologic outcome of implant-supported restorations in the treatment of partial edentulism. part I: a longitudinal clinical evaluation. *Clin Oral Implants Res.* 2002 Aug;13(4):381-9. [Medline: [12175375](#)] [doi: [10.1034/j.1600-0501.2002.130406.x](#)]

To cite this article:

Tzerbos F, Sykaras N, Tzoras V. Restoration-guided implant rehabilitation of the complex partial edentulism: a clinical report
J Oral Maxillofac Res 2010 (Jan-Mar);1(1):e8

URL: <http://www.ejomr.org/JOMR/archives/2010/1/e8/e8ht.pdf>

doi:[10.5037/jomr.2010.1108](https://doi.org/10.5037/jomr.2010.1108)

Copyright © Tzerbos F, Sykaras N, Tzoras V. Accepted for publication in the JOURNAL OF ORAL & MAXILLOFACIAL RESEARCH (<http://www.ejomr.org/>), 24 November 2009.

This is an open-access article, first published in the JOURNAL OF ORAL & MAXILLOFACIAL RESEARCH, distributed under the terms of the [Creative Commons Attribution-Noncommercial-No Derivative Works 3.0 Unported License](https://creativecommons.org/licenses/by-nc-nd/3.0/), which permits unrestricted non-commercial use, distribution, and reproduction in any medium, provided the original work and is properly cited. The copyright, license information and link to the original publication on (<http://www.ejomr.org/>) must be included.